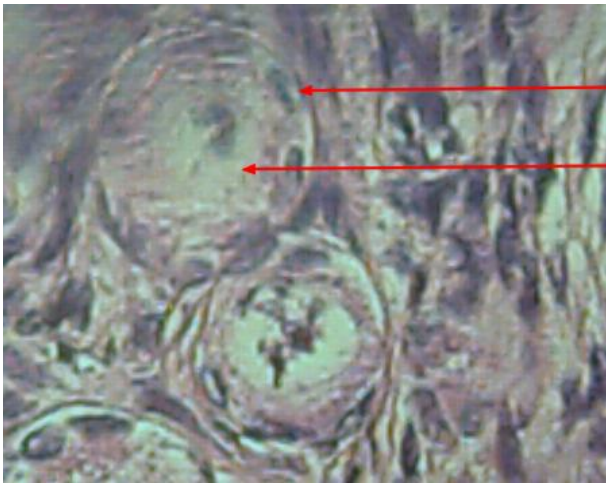
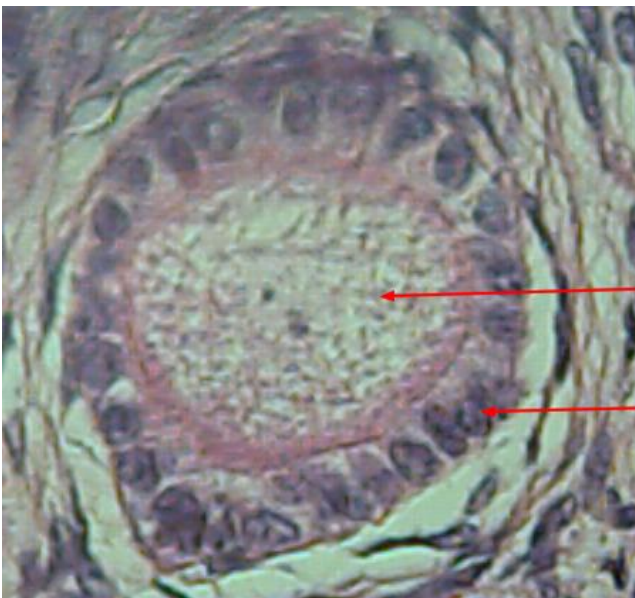
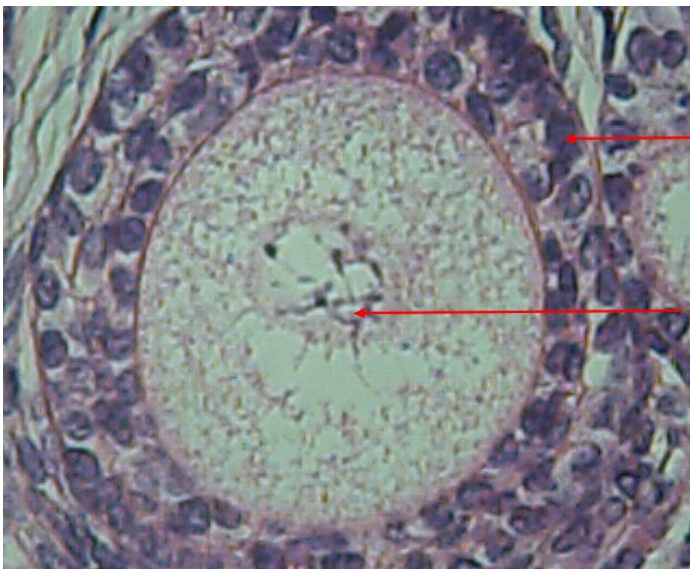
Cellules folliculaires

Ovocyte



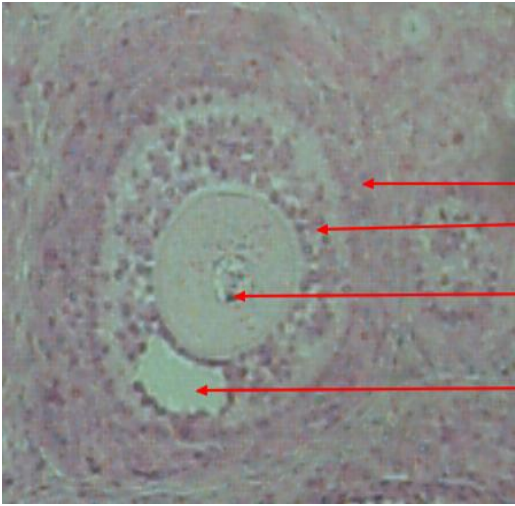
Ovocyte

Cellules
folliculaires

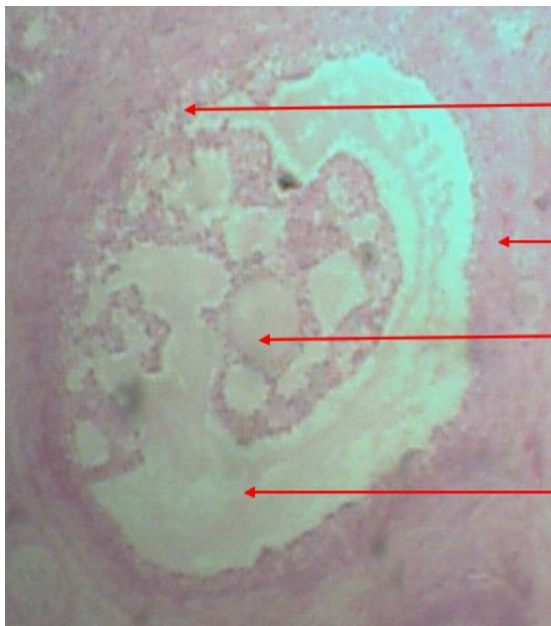


Cellules
folliculaires

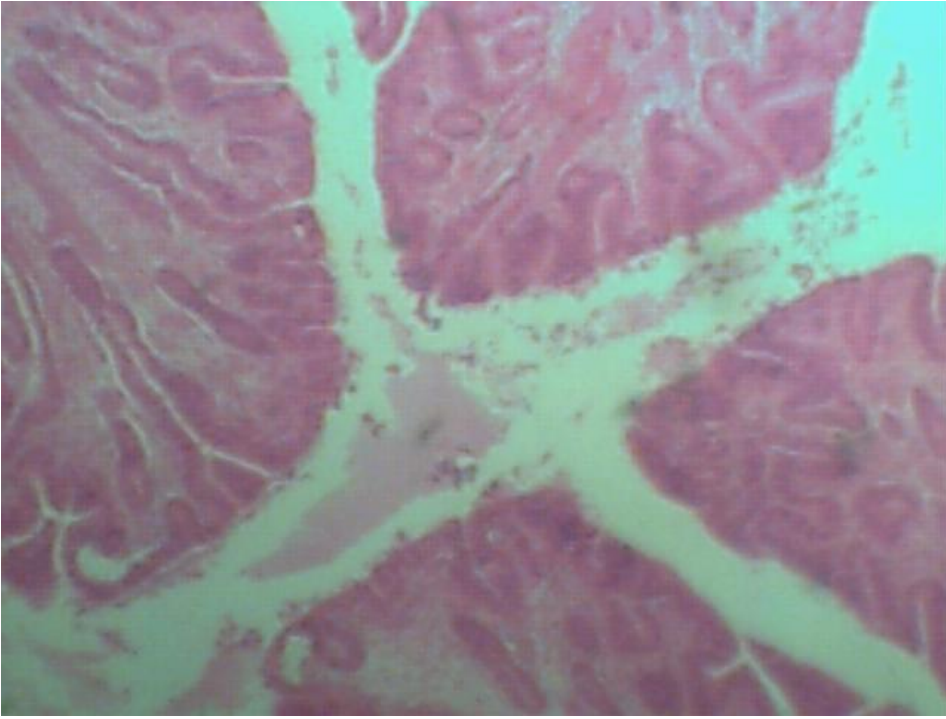
Ovocyte



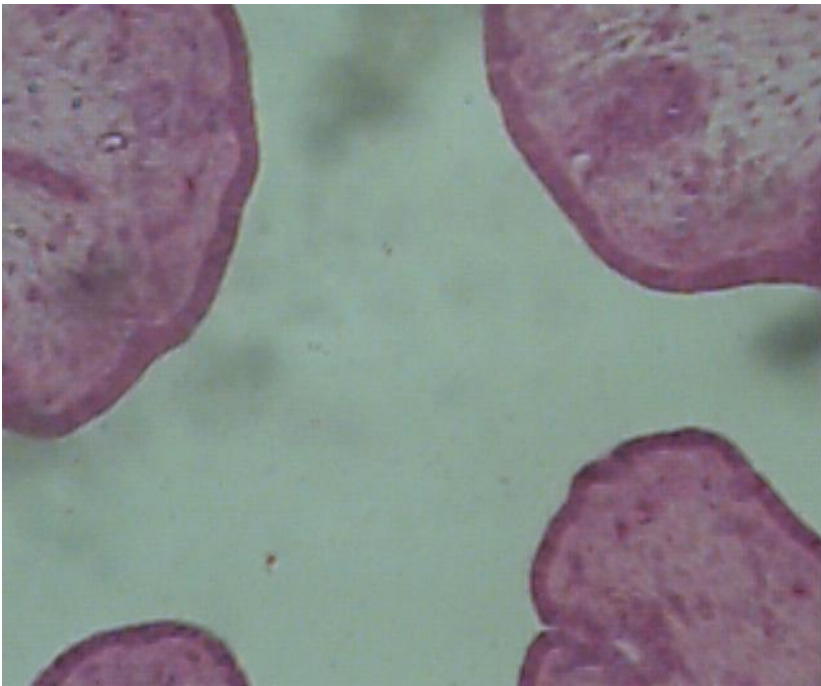
Thèques
granulosa
ovocyte
Cavité



granulosa
thèques
Ovocyte
Cavité



coupe d'utérus en en phase lutéinique de lapine



coupe d'utérus en phase folliculaire de lapine